

Management of Zygomatic Arch Fracture in Polycythemia Vera Patient-A Case Report

R.S.G. SATYASAI, PRASANNA PATRUNI*, P K NAGASAI,
SRAVANI, V MEGHANA and P DIVYA

Department of Oral and Maxillofacial Surgery, Vishnu Dental College, Bhimavaram,
West Godavari, Andhra Pradesh, India.

Abstract

Polycythemia vera (PV) is a myeloproliferative neoplastic condition characterized by an unregulated synthesis of red blood cells (RBCs). There is often simultaneous stimulation of the megakaryocytic and myeloid lineages, this causes an increase in the synthesis of white blood cells and platelets.² As a result, there is an increased risk of thrombosis and bleeding. Due to the extensive vascular network of the face and jaw⁷ and limited surgical access to perform hemostasis, traumatic injuries and surgical procedures are among the most common causes of increased blood loss. Zygomatic bone fracture is one of the most frequent fractures of the facial skeleton. The zygomatic bone is a strong bone that supports the maxilla and the skull base. However, its prominence makes it highly susceptible, mainly when impact occurs on both sides of the face.⁴ Facial bone fractures are associated with 1–11% excess blood loss. These complications have the potential to increase perioperative morbidity and mortality significantly. Adequate precautions must be taken in treating these patients for successful outcomes. The management of patients with PV includes therapeutic preoperative phlebotomy, increased fluid intake, and antiplatelet therapy. This report demonstrates the management of a complex procedure such as maxillofacial trauma in a PV patient with a normal coagulation profile.



Article History

Received: 20 October 2022

Accepted: 13 January 2023

Keywords

Hemorrhage;
Myeloproliferative
neoplastic disorders;
Polycythemia Vera;
Zygomatic Arch Fracture.

Introduction


The first description of PV appeared in 1892.¹ In 1951, PV and associated diseases were referred to as "myeloproliferative disorders" (MPDs).

To reflect the consensus that these disorders constitute neoplasms 1, the WHO reclassified MPD as "myeloproliferative neoplasms" (MPN) in 2008. PV is a rare chronic disease that causes

CONTACT Prasanna Patruni ✉ satyasai.romala4@gmail.com 📍 Department of Oral and Maxillofacial Surgery, Vishnu Dental College, Bhimavaram, West Godavari, Andhra Pradesh, India.



© 2022 The Author(s). Published by Enviro Research Publishers.

This is an  Open Access article licensed under a Creative Commons license: Attribution 4.0 International (CC-BY).

Doi: <http://dx.doi.org/10.12944/EDJ.04.02.03>

myeloproliferation. Because RBCs are produced in excess in the bone marrow compared to white blood cells and platelets an abnormally high number of RBCs circulate in the blood,¹ resulting in hyper viscosity and a greater risk for thrombosis.¹ Due to the built-in thrombogenic potential of the blood, there is an increased risk of myocardial infarction, heart attack, cerebrovascular events, pulmonary infarctions, deep vein thrombosis, and portal hypertension. Perioperative monitoring of these patients is essential to avoid complications. To avoid complications, it is important to consider prophylactic procedures before surgery.³ Therapeutic phlebotomy, hemodilution, and antiplatelet therapy are suggested and mostly used as prophylactic procedures recommended during the perioperative period. The primary outcomes considered in the management are to enhance the health benefits¹ while minimizing negative effects by encouraging procedures¹ to be performed at appropriate times with appropriate precautions.¹

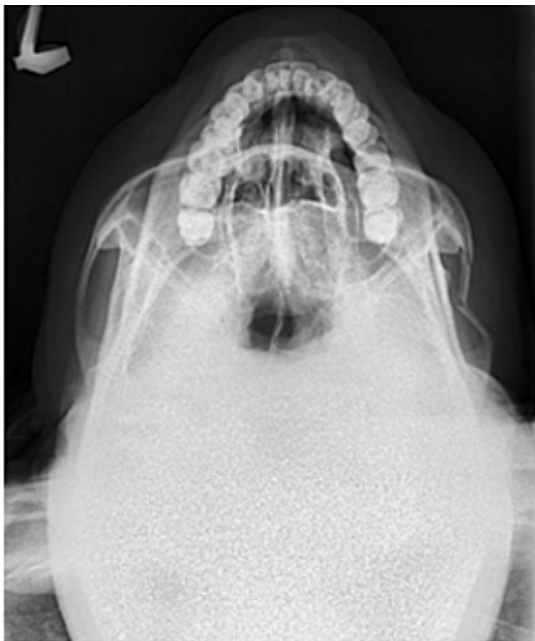

Fig. 1: Pre operative radiograph

Case Report

A 30-year-old male patient presented to oral surgery department with a chief complaint of pain on the right side of his face for 3 days. He gave an alleged history of trauma from a loose ceiling fan falling on his face. There was no loss of consciousness or bleeding from

the ear, nose, or mouth. The medical and surgical history was unremarkable, and his vital signs were within normal limits. There has been a history of smoking and alcohol consumption for the past 12 years. On extraoral examination, he had a restricted mouth opening of 2.5 cm. Tenderness, crepitus, and depression were noted in the preauricular and temporal regions on the right side of the face. On intraoral examination, the occlusion was satisfactory. Radiographic examination using a submentovertex view (SMV) (Fig. 1) revealed a fracture of the right zygomatic arch.

A routine preoperative workup including a complete blood count, coagulation profile, and viral markers was performed, revealing a hemoglobin (Hb) level of 20.2 g/dL, a hematocrit¹ of 58.6%, a total RBC count of 6.44 million/cumm, an RDW-CV of 14.3%. Total white blood cell and platelet counts, as well as bleeding and clotting times, were all within the normal range. To exclude technical errors, the whole blood count was repeated in another laboratory, and the results were consistent with the previous values. The blood erythropoietin level was normal. Arterial blood gas analysis (ABG) revealed that the patient's oxygenation was normal. The patient denied any recent vomiting or diarrhea, living at high altitudes, or with congenital diseases. The patient was referred to a physician for further evaluation. He was also advised to have a chest X-ray, an ECG, liver and renal function tests,⁷ all of which came back normal. Considering the history, clinical, and lab findings, the patient was diagnosed as suffering from polycythemia vera. The treatment plan was discussed with the primary care physician, and after obtaining eligibility for surgery, the case was scheduled for zygomatic arch reduction under local anesthesia. Considering the thrombogenic potential of the blood, preoperative therapeutic phlebotomy (about 350 mL) to reduce the hematocrit to 40%, antiplatelet treatment with Aspirin 150 mg, 12th hourly, was started on the preoperative day and continued until the first postoperative day as recommended by the physician. On the day of surgery, the patient was advised to drink plenty of fluids, and 1 pint of DNS and NS were infused for hemodilution before surgery.

An intraoral vestibular incision was placed in the maxillary right molar area. Dissection was performed

to reach the zygomatic arch. The Rowe Zygomatic elevator was passed under the zygomatic arch, and the arch was elevated. A mouth opening of 5 cm was achieved and the stability of the reduced arch was checked using extraoral digital pressure. The incision was closed with 3-0 vicryl round body absorbable sutures. The reduction was confirmed by radiograph (SMV) (Fig. 2) and compared with the preoperative radiograph.

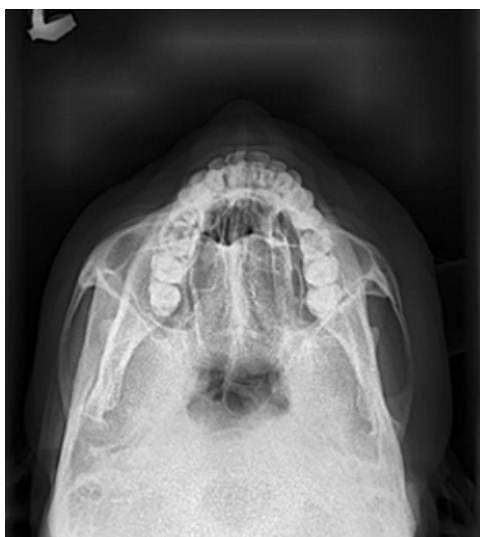

Fig. 2: Post operative radiograph

There were no intraoperative complications, the patient was transferred to the recovery room and hemodynamic parameters were carefully monitored. Intraoperative blood loss was calculated, and crystalloids were used to replace it. He was discharged on the third postoperative day with satisfactory healing and was advised to quit smoking, undergo therapeutic phlebotomy, and have a biannual medical check-up. The sutures were removed after 10 days, and there were no postoperative complications during follow-up visits.

Discussion

Maxillofacial surgery has advanced to the point where patients with intricate bleeding diathesis can undergo various surgical procedures safely.⁵ Providing patient care is challenging especially when there is unexpected hemorrhage clinically. This can occur in two ways, intraoperatively or postoperatively. Because of the extensive vasculature in the head and neck area,⁶ as well as limited access through intra-oral sites, most maxillofacial procedures are associated with intra- or post-operative bleeding. In an otherwise healthy patient, this bleeding is self-limiting or controllable.⁷ However, the risk of bleeding increases in patients with bleeding disorders, where even minor procedures can cause prolonged bleeding episodes.¹

Table 1: Signs and Symptoms of Polycythemia Vera⁹

SYMPTOMS	SIGNS
<p>More common</p> <ul style="list-style-type: none"> • Fatigue • Headache • Dizziness • Tinnitus • Vision changes • Insomnia • Gastritis • Aquagenic pruritus <p>Less common</p> <ul style="list-style-type: none"> • Erythromelalgia • gum bleeding • gastrointestinal (GI) bleeding • Epistaxis • deep venous thrombosis • pulmonary embolism • stroke 	<ul style="list-style-type: none"> • Splenomegaly • Systolic Hypertension • Skin Plethora • Hepatomegaly • Budd-Chiari syndrome

Polycythemia vera (PV) is caused by a mutation in the JAK-2 gene. The etiology of the disease is unknown. The disease is rare, with an incidence of 0.7–2.6/1 lakh people annually. Men are more commonly affected than women, and the incidence increases with age. PV can occur spontaneously (primarily) due to genetic abnormalities or secondarily due to a long-term lack of oxygen, such as at high

altitudes or from cigarette smoking, also known as smoker's polycythemia or chronic obstructive pulmonary disease.⁸ The signs and symptoms of the disease are shown in Table 1. The cause of the disease in this case was unknown. However, chronic smoking was thought to be a contributing factor and was provisionally diagnosed as secondary polycythemia vera

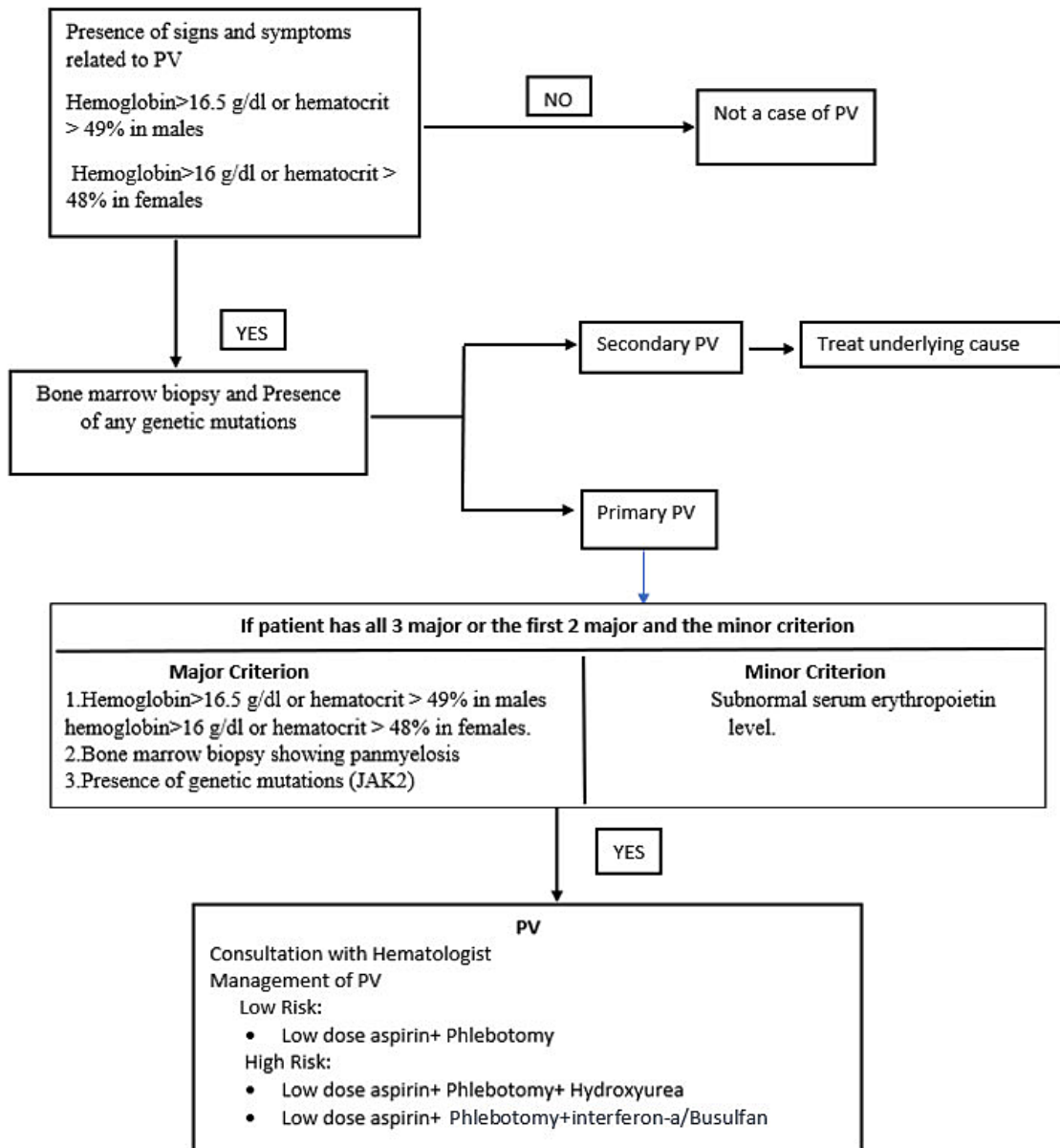


Fig. 3: Diagnostic Criteria for PV⁸

Polycythemia vera (PV) causes an increase in erythrocyte count i, e. 6 to 12 million/mm, and Hb level greater than 18-24 gm/dL, resulting in increased viscosity of blood and thrombosis.¹ The disease is considered PV when hematocrit is greater than 48% in females and greater than 52% in males. With a hematocrit greater than 55%, there is a significant increase in blood viscosity, which is thrombogenic, as a result, atherosclerosis and cardiovascular disease are more likely to occur. Hematocrit beyond 60% can be fatal and put the patient at risk for arterial as well as venous thrombosis. Leukocytosis and thrombocytosis may also be present. The diagnostic criteria are explained in Figure 3

Surgeons and anesthesiologists must deal with a PV patient whose capacity to endure surgery is hampered by hematologic abnormalities. The most prevalent cause of hypoxia in these individuals is increased blood viscosity.^{1,7} These surgical patients are at an elevated risk of perioperative thrombosis and bleeding diathesis,⁷ which can be reduced by therapeutic phlebotomy and avoidance of extreme dehydration.⁷ A dislodged thrombus can cause several life-threatening conditions such as myocardial infarction, pulmonary infarctions, cerebrovascular events and so on.¹¹ Inadequate control of the thrombogenic tendency can thus lead to life-threatening conditions. A preoperative ECG is mandatory to rule out cardiovascular abnormalities. In such conditions, various techniques have been proposed to reduce the thrombogenic tendency of blood. These include hemodilution, therapeutic phlebotomy, antiplatelet therapy, myelosuppressive therapy, interferon alfa, etc.^{5,9} However, myelosuppressive therapy is known to transform polycythemia into leukemia. Patients with polycythemia vera can be divided into low-risk (i.e. with a history of thrombosis, age > 60 years) and high-risk (no history of thrombosis, age < 60) groups. In our case, the patient can be classified as low risk because there is no previous history of thrombosis and his age is less than 60 years. Myelosuppressive treatment is indicated only in high-risk patients.¹⁰ Therapeutic phlebotomy and antiplatelet treatment without myelosuppressive treatment were therefore recommended for this patient.

Patients suffering from PV who undergo surgery are at a greater risk for bleeding and thrombosis. Consequently, it is critical to screen the patients preoperatively to ensure that abnormal counts are optimized to balance the urgency of surgery against the risk i, e. bleeding, and thrombosis. Perioperative management include⁷

- Involvement of the hematologist to optimize count control and tailor the perioperative plan.
- Using standard protocols for antithrombotic prophylaxis.
- The patient should undergo preoperative screening for coagulation tests, aVWS, and platelet function tests if he or she has a history of bleeding.

Conclusion

To summarize elevated hematocrit, normal arterial oxygenation, and normal erythropoietin levels²⁰ indicate PV.⁷ It is crucial to recognize a patient with PV because avoiding hypoxia is a critical component of ideal anesthesia.¹ Managing such patients successfully requires phlebotomy, adequate hydration, and recognition of thrombotic and bleeding problems. It is imperative to perform this duty with sound clinical judgment and a thorough understanding of the pathophysiology of PV.²⁰ This case report demonstrates that a complex procedure such as the treatment of maxillofacial trauma can be performed safely in patients with PV.

Acknowledgments

The author would like to thank the head of the Department and faculty members of the Department of Oral and Maxillofacial Surgery Vishnu Dental College for their guidance and support to complete this article.

Funding

There is no financial or funding support for this article.

Conflict of Interest

No

References

1. Grover HS, Kapoor S, Kaushik N. Polycythemia vera dental management -case report. *J Anesth Crit Care Open Access*. 2016;5(2):11–12. DOI: 10.15406/jaccoa.2016.05.00177
2. Lu X, Chang R. Polycythemia Vera. 2022 Apr 28. In: Stat Pearls [Internet]. Treasure Island (FL): Stat Pearls Publishing; 2022 Jan–. PMID: 32491592.
3. Adam AA, Zhi L, Bing LZ, Zhong Xing WU. Evaluation of treatment of zygomatic bone and zygomatic arch fractures: a retrospective study of 10 years. *J Maxillofacial Oral Surg*. 2012 Jun;11(2):171-6. Doi: 10.1007/s12663-011-0294-x.
4. Wilson, Damien Jonas. (2019, February 27). Zygomatic Fractures. News-Medical. Retrieved on October 19, 2022, from <https://www.news-medical.net/health/Zygomatic-Fractures.aspx>.
5. Lichtman MA, Beutler E, Kipps TJ, Seligsohn U, et al. Eds. Williams Hematology. 7th ed. McGraw-Hill Companies. New York, NY; 2006:779-803.
6. Amat, Shaila; Deepa, C; Priolkar, Samita; Nazareth, Marilyn (2012). A case of polycythemia vera for orthopedic surgery: Perianesthetic considerations. *Saudi Journal of Anaesthesia*, 6(1), 87–. doi:10.4103/1658-354x.93077
7. Aliabadi E, Malekpour B, Tavanafar S, Karimpour H, Parvan M. Intraoperative Blood Loss in Maxillofacial Trauma Surgery. *Ann Maxillofac Surg*. 2020;10(1):164-167. doi: 10.4103/ams.ams_165_19
8. Brian J. Stuart, Lt, Mc, Usnr, And Anthony J. Viera, Lcdr, Mc, Usnr *Am Fam Physician*. 2004;69(9):2139-2144
9. Iurlo, Alessandra & Cattaneo, Daniele & Bucelli, Cristina & Baldini, Luca. (2020). New Perspectives on Polycythemia Vera: From Diagnosis to Therapy. *International Journal of Molecular Sciences*. 21. 5805. 10.3390/ijms21165805.
10. Tefferi, Ayalew & Vannucchi, Alessandro & Barbui, Tiziano. Polycythemia vera treatment algorithm, *Blood Cancer Journal* 2018 doi: 8. 10.1038/s41408-017-0042-7.
11. Hans Carl Hasselbalch. Smoking as a contributing factor for the development of polycythemia vera and related neoplasms, *Leukemia Research*, Volume 39, Issue 11, 2015, Pages 1137-1145
12. Raedler LA. Diagnosis and Management of Polycythemia Vera: Proceedings from a Multidisciplinary Roundtable. *Am Health Drug Benefits*. Oct;7(7 Suppl 3):S36-47 2014
13. Stuart, Brian J, and Anthony J Viera. "Polycythemia vera." *American family physician* 69 9 (2004): 2139-44
14. Tefferi A, Barbui T. Polycythemia vera and essential thrombocythemia: 2019 update on diagnosis, risk-stratification and management. *Am J Hematol*. 2019 Jan;94(1):133-143.
15. Cerquozzi S, Barraco D, Lasho T, Finke C, Hanson CA, Ketterling RP, Pardanani A, Gangat N, Tefferi A. Risk factors for arterial versus venous thrombosis in polycythemia vera: a single center experience in 587 patients. *Blood Cancer J*. 2017 Dec 27;7(12):662. doi: 10.1038/s41408-017-0035-6.
16. cansa.org.za
17. Bergeron JM, Raggio BS. Zygomatic Arch Fracture. [Updated 2022 Jun 27]. In: Stat Pearls [Internet]. Treasure Island (FL): StatPearls Publishing; 2022
18. Agrawal, Mohit, Hu Weihsin, Abhishek Pandey, and Balram Garg. "Benign cementoblastoma : a case report with review of the literature", *Egyptian Journal of Oral &Maxillofacial Surgery*, 2014.
19. Vaibhav Jain, Himani Garg. "Intra-oral reduction of zygomatic fractures", *Dental Traumatology*, 2017
20. Shaila Kamat, C. Deepa, Samita Priolkar, Marilyn Nazareth. "A case of polycythemia vera for orthopedic surgery: Perianesthetic considerations", *Saudi Journal of Anaesthesia*.